



PATIENT

Billy Galena

SPECIES

Feline

BREED

DSH

SEX

Male Neutered

AGE

6.11.11

WEIGHT

11.1lbs

INTERPRETED BY

Maggie Machen Lamy,
DVM, DACVIM
(Cardiology)

HOSPITAL NAME

Prime Care Animal
Hospital

REFERRING VET

Dr. Martin

INVOICE

25940

DATE

8.22.22

PRESENTING CLINICAL SIGNS

History: Grade 2/6 systolic murmur.
-Pertinent abnormal PE/Chem/CBC/UA Results: NSF.
-Current medications: None.
-Blood pressure: 116mmHg with doppler.
-Sedation used: Not required to complete full diagnostic ultrasound.
-Pertinent previous ultrasound results: No previous.
-STAT: Not requested.
-Imaging performed by: Stephanie Warga RDCS, RVT.

ECHOCARDIOGRAM FINDINGS

2D, m-mode, color flow and doppler imaging is available. The left ventricular wall is remodeled with a focal septal thickening. The remainder of the LV wall measures normal. There is a diffusely hyperechoic endocardium consistent with fibrosis. The papillary muscles are mildly remodeled and hyperechoic. The endocardium also appears remodeled. The left atrium is normal in size. The right atrium is normal in size. The right ventricle appears normal. The mitral valve is normal in structure and mobility. No MR. Trace TR is visualized. Blood flow through the RVOT is normal in velocity. No pleural or pericardial effusion seen. No obvious cardiac tumors.

CARDIAC CHART

FELINE CARDIAC PARAMETERS	BODY WEIGHT (kg)	HR (BPM)	IVSd (cm) <small>(Moise, Pipers)</small>	LVIDd (cm) <small>(Moise, Pipers)</small>	LWVd (cm) <small>(Moise, Pipers)</small>	FS (%)	EF (%)
NORMAL PARAMETER	-----	150-240	3.5-0.55	<2 (mean 1.5)	3.5-0.55	35-67	80-100
PATIENT	5.0	NM	0.40	1.36	0.32	53	87
FELINE CARDIAC PARAMETERS	LA/AO <small>(Boon)</small>	LA/AO HEART BASE (Swe) <small>(Abbott)</small>	LA 2D short axis Base view (cm) <small>(Abbott)</small>		LVOT VEL (m/s)	RVOT VEL (m/s)	E max (m/s)
NORMAL	<1.5	<1.3	<1.2		<1.6	<1.3	<0.9
PATIENT	NM	1.2	1.2		1.0	0.9	NM

Adapted from June Boon, Veterinary Echocardiography, 1998
Abbott J & MacLean H JVIM 2006;20: 111-119, Moise et al. Am J Vet Res 47:1476, 1986. Pipers et al. Am J Vet Res 40:882, 1979.

INTERPRETATION OF THE FINDINGS & FURTHER RECOMMENDATIONS

Focal LV hypertrophy is present in addition to LV remodeling, which may be indicative of early hypertrophic disease or may simply represent a normal variant. Regardless, the LA remains normal which would indicate clinical stability. Serial echocardiography will be necessary to determine progression and clinical significance. Additionally, no definitive cause is identified for the murmur in this study, making it likely benign and secondary to tachycardia/stress.

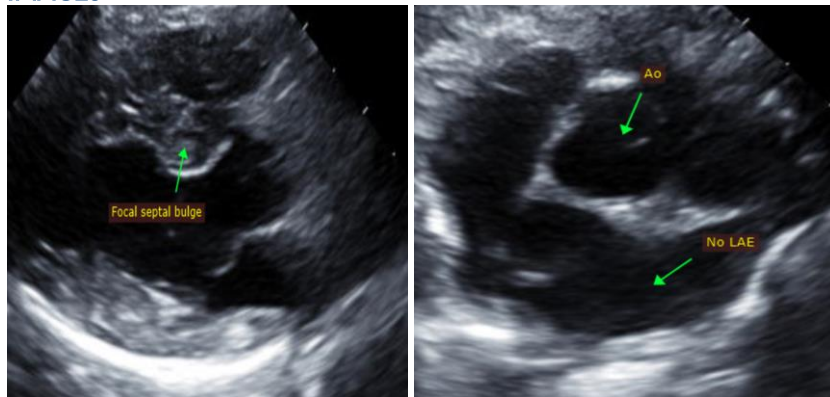
With a normal LA dimension, no medications are indicated.

Anesthetic risk is mild, however any cat with this degree of fibrosis and diastolic dysfunction will be at risk for iatrogenic IV fluid overload should they be needed in the future.

Monitor for any development of clinical signs, including labored breathing or signs of a blood clot (paralysis, neurologic change).

A recheck echocardiogram is recommended in 6-12 months to screen for any evidence of progression.

IMAGES



The information and recommendations provided are based on the images presented by the referring veterinarian. No evaluation can be communicated regarding pathology that was not visible in the image/video clips provided.

Thank you for this referral. This report was generated using transcription software, and minor dictation errors may be present. If the clinical or image interpretation does not parallel your findings or if I can be of any further assistance, please contact me.

Maggie Machen Lamy, DVM
Diplomate of the American College of Veterinary Internal Medicine (Cardiology)
info@sonopath.com